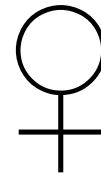


**McNeil, Julian. “Complete Heart Block in
A Caucasian Woman with Behçet’s
Disease: A Case Report.”**

JOURNAL OF MEDICAL CASE REPORTS 10.1 (2016): 1

PART 1

lightheadedness
muscular weakness
blurred vision
feeling faint
feeling sick
abnormal heartbeat



48



ECG → heart block → pacemaker

Troponin levels → no damage

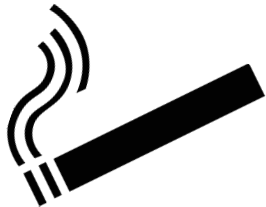PART 2A

Some weeks later : diarrhea

Recent history

Genital and mouth ulcers
swollen and tender joints,
Red eyes

History



Clot in right leg

PART 2B

3 months before : 

chest pain

inflammation of heart muscle

normal heartbeat

fluid around heart

swollen right knee

ulcers inside mouth and on vulva

DIAGNOSIS

Tests

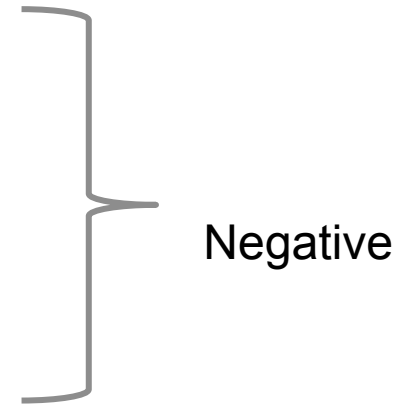
Bowel disease

Unhealed skin wounds

Autoimmune diseases

Blood and stool immune tests

Internal examination of digestive system - ulcer



Ulcers + joint inflammation + ulcer in digestive tract + inflamed eyes → Behçet's disease

TREATMENT & FOLLOW UP

Inflammation : prednisalone

Diarrhea : sulfasalzine

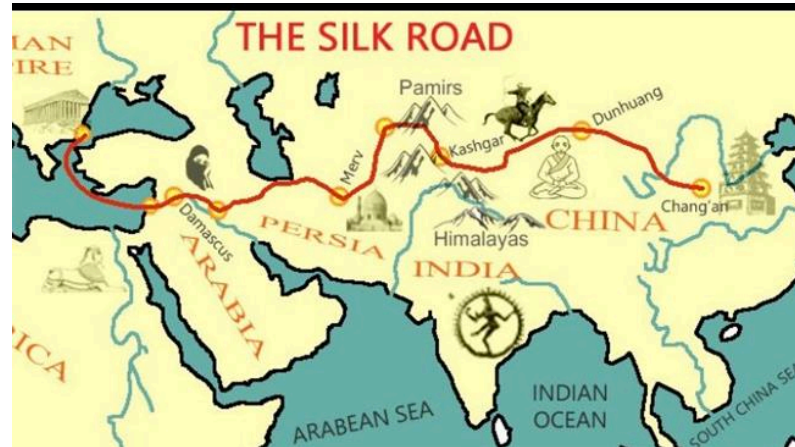


Symptom free 1 & 3 months later

POINTS OF NOTE

Behçet's disease

+ common in ♂ from



1st case of heart block and BD in a caucasian ♀

Recommendation

♥ problems can be fatal → if BD check ♥